

Guidelines for the management
of **asymptomatic** women
with screen-detected abnormalities

Endorsed by NHMRC, 9 June 2005

Ian Hammond

Clinical Professor, University of Western Australia

13th Annual Women's Health Conference

Saturday 25th February 2006

Guideline Review Group Membership

Chair: Ian Hammond

Deputy Chair: Annabelle Farnsworth

- Stephanie Bell
- Maureen Ramsden
- Sheena Thornton
- Penny Blomfield
- Chris Hunter
- Margaret Davy
- Gerry Wain
- Elizabeth Hindmarsh
- Ruth McNair
- Margaret Culpan

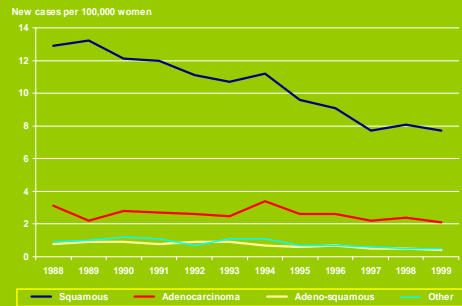
- Heather Mitchell
- Alex Barratt
- David Roder
- Liz Pugh / Vicki Shaw
- Marion Saville
- Greg Sterrett
- Richard Williams
- Paul Shield
- Luke Connelly
- Ian Frazer
- Secretariat: NSW Cervical Screening Program

Guidelines for the management
of **asymptomatic** women
with screen-detected abnormalities

Endorsed by NHMRC, 9 June 2005

Implementation date: 3 July 2006

Age-standardised incidence rates of cervical cancer by histological type,
women aged 20 - 69 years, Australia 1988 - 1999



Why change?

- Previous 1994 guidelines rescinded by NHMRC
- Terminology not internationally consistent
- New knowledge about HPV
- Unnecessary investigation & treatment
- Unnecessary anxiety about cancer
- Costs of treatment (physical, fertility, emotional, psychosexual, financial)

What am I talking about today

- What are the changes?
- What is the underpinning evidence or rationale for the changes?
- How will they affect you?

The guidelines are not prescriptive (except to laboratories).

Clinicians and women can still customise the management of individual women.

6 main areas of change

- New terminology AMBS 2004
- Recommended management for women
 - with low grade abnormalities on Pap smear
 - with low grade abnormalities on biopsy
 - with glandular abnormalities on Pap smear
- Reporting of normal endometrial cells on Pap smears
- Post-treatment care after a high-grade abnormality

Your 22 yr old patient has her 1st Pap smear which is reported as Low grade epithelial abnormality with atypical cells. What would you recommend ?

1. Repeat Pap every 12 months until normal or high grade change occurs
2. Repeat Pap in 6- 12 months and if still present refer for colposcopy
3. Routine Pap in 24 months
4. Immediate colposcopy

Your 22 yr old patient has her 1st Pap smear which is reported as Low grade epithelial abnormality with atypical cells. What would you recommend ?

1. **Repeat Pap every 12 months until normal or high grade change occurs**
2. Repeat Pap in 6- 12 months and if still present refer for colposcopy
3. Routine Pap in 24 months
4. Immediate colposcopy

Your 22 yr old patient has her 1st Pap smear which is reported as Low grade epithelial abnormality with HPV cell changes. What would you recommend ?

1. Repeat Pap in 6 months and if still present refer for colposcopy
2. Repeat Pap in 6 & 12 months and if still present refer for colposcopy
3. Routine Pap in 24 months
4. Immediate colposcopy

Your 22 yr old patient has her 1st Pap smear which is reported as Low grade epithelial abnormality with HPV cell changes. What would you recommend ?

1. Repeat Pap in 6 months and if still present refer for colposcopy
2. **Repeat Pap in 6 & 12 months and if still present refer for colposcopy**
3. Routine Pap in 24 months
4. Immediate colposcopy

Your 22 yr old patient has her 1st Pap smear which is reported as Low grade epithelial abnormality with CIN1cell changes. What would you recommend ?

1. Repeat Pap in 6 months and if still present refer for colposcopy
2. Repeat Pap in 12 months and if still present refer for colposcopy
3. Routine Pap in 24 months
4. Immediate colposcopy

Your 22 yr old patient has her 1st Pap smear which is reported as Low grade epithelial abnormality with CIN1cell changes. What would you recommend ?

1. Repeat Pap in 6 months and if still present refer for colposcopy
2. Repeat Pap in 12 months and if still present refer for colposcopy
3. Routine Pap in 24 months
4. **Immediate colposcopy**

Your 36 yr old patient has her routine Pap smear which is reported as "inconclusive with possible high grade squamous change". She is asymptomatic. What would you recommend ?

1. Repeat Pap in 6 months and if still present refer for colposcopy
2. Repeat Pap in 12 months and if still present refer for colposcopy
3. Immediate colposcopy
4. Immediate colposcopy only if she is symptomatic

Your 36 yr old patient has her routine Pap smear which is reported as "inconclusive with possible high grade squamous change". She is asymptomatic. What would you recommend ?

1. Repeat Pap in 6 months and if still present refer for colposcopy
2. Repeat Pap in 12 months and if still present refer for colposcopy
3. **Immediate colposcopy**
4. Immediate colposcopy only if she is symptomatic

Your 26 yr old patient has her 3rd routine Pap smear which is reported as "atypical glandular cells, possibly reactive". She is asymptomatic. What would you recommend ?

1. Repeat Pap in 6 months and if still present refer for colposcopy
2. Repeat Pap in 12 months and if still present refer for colposcopy
3. Immediate colposcopy
4. Immediate colposcopy only if she is symptomatic

Your 26 yr old patient has her 3rd routine Pap smear which is reported as "atypical glandular cells, possibly reactive". She is asymptomatic. What would you recommend ?

1. **Repeat Pap in 6 months and if still present refer for colposcopy**
2. Repeat Pap in 12 months and if still present refer for colposcopy
3. Immediate colposcopy
4. Immediate colposcopy only if she is symptomatic

Your 26 yr old patient has her 3rd routine Pap smear which is reported as a "high grade glandular cell abnormality". She is asymptomatic. What would you recommend ?

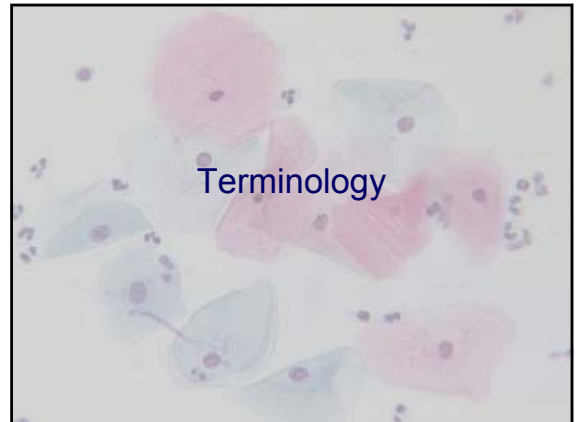
1. Repeat Pap in 6 months and if still present refer for colposcopy
2. Repeat Pap in 12 months and if still present refer for colposcopy
3. Immediate colposcopy
4. Immediate colposcopy only if she is symptomatic

Your 26 yr old patient has her 3rd routine Pap smear which is reported as a "high grade glandular cell abnormality". She is asymptomatic. What would you recommend ?

1. Repeat Pap in 6 months and if still present refer for colposcopy
2. Repeat Pap in 12 months and if still present refer for colposcopy
3. **Immediate colposcopy**
4. Immediate colposcopy only if she is symptomatic

6 main areas of change

- **New terminology AMBS 2004**
- **Recommended management for women**
 - with low grade abnormalities on Pap smear
 - with low grade abnormalities on biopsy
 - with glandular abnormalities on Pap smear
- **Reporting of normal endometrial cells on Pap smears**
- **Post-treatment care after a high-grade abnormality**



2005 Terminology	1994 Terminology
Unsatisfactory	Unsatisfactory
Negative	Negative
Squamous abnormalities - Possible low-grade - Low-grade - Possible high-grade - High-grade	Low-grade abnormalities - Non-specific minor change - HPV effect - CIN 1 - Glandular changes
	Inconclusive
Glandular abnormalities	High-grade abnormalities - CIN 2, CIN 3, AIS - Cancer

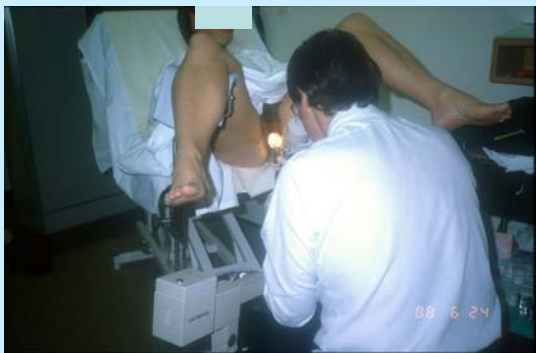Rationale for terminology change

- Poor reproducibility for distinguishing between the three subtypes of low-grade cytology
- New knowledge that low-grade cytology mostly represents the changes of HPV infection in squamous cells
- Brings Australian terminology closer to the international Bethesda terminology

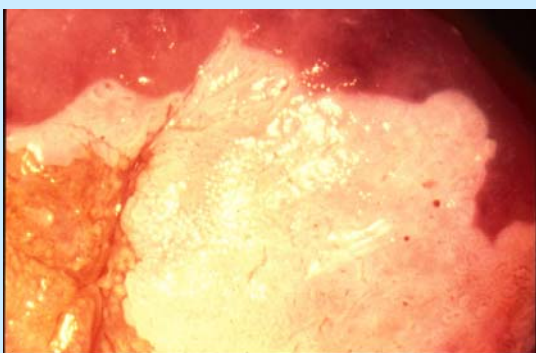
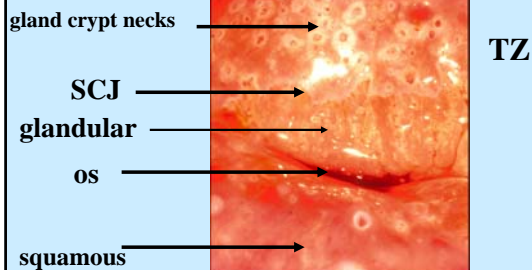
Management of abnormal smears is now simplified into two main streams.



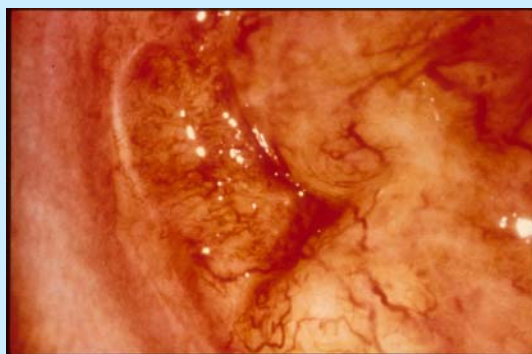
- Squamous abnormality
 - Possible low-grade
 - Low-gradeRepeat Pap at 12 months
- Possible high-grade
- High grade
- Glandular abnormality
 - Atypical cells
 - Possible high-grade
 - High gradeColposcopy



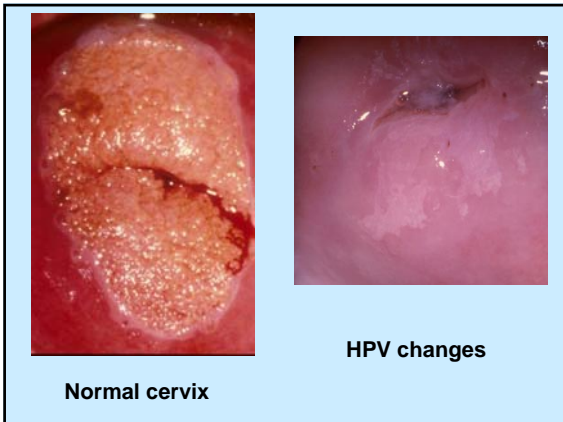
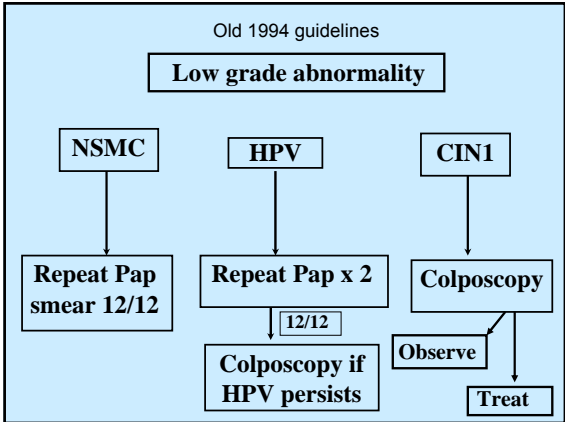
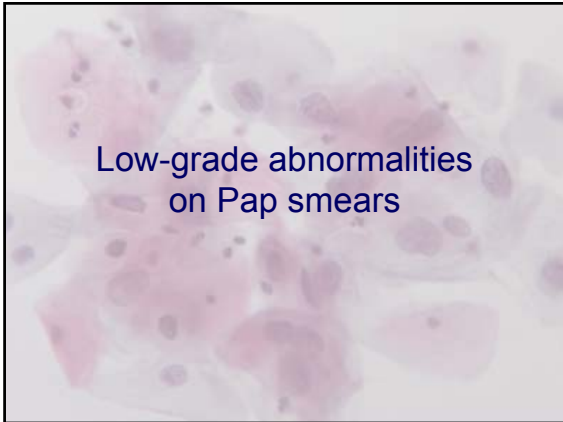
COLPOSCOPY



CIN3



Cancer of the Cervix



CANCER

Outcome after a Cervical Cytology Report of Low-Grade Squamous Abnormality in Australia

Heather Mitchell, *et al.*

Women's Cancer Control Group, Cancer Council Australia

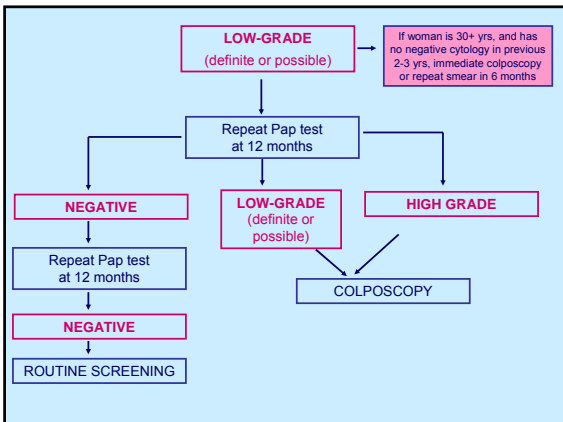
BACKGROUND: The current study was undertaken to assess with providing an evidence-based approach to the management of women with cervical cytology reports of low-grade squamous abnormality as used in the Australian organized screening program.

METHODS: Using the Pap Test Register, an audit was performed of the outcome over 24 months of Australian women who received an initial cervical cytology report of low-grade squamous abnormality in 1999.

RESULTS: Information was available for 76,706 of the 86,761 women whose first cytology report in 1999 was of a low-grade squamous abnormality. Forty-one cases of histologically confirmed cervical carcinoma were diagnosed during the subsequent 24 months (19 Stage I), 13 Stage II or worse). Five of the 46 women who were diagnosed with Stage I carcinoma during the 24 months following had an immediate cervical biopsy of histologically interpreted abnormality. The first of cervical carcinoma diagnoses during the 24 months was 40% (16/41) carcinoma in situ, 40% (16/41) in the vagina with microscopic stromal change (stage I cytology), 14% (6/41) in the cervix with microscopic stromal change (stage I cytology), 14% (6/41) in the cervix with histologic stromal change (stage I cytology), and 14% (6/41) in the cervix with histologic stromal change (stage I cytology).

CONCLUSIONS: Cervical carcinoma is a rare event within 2 years of a cytology report of low-grade squamous abnormality in Australia. A simplified management for low-grade squamous abnormality reports should be considered for Australia, with ongoing management for management women. *Cancer of Cancer J (published 2005) 10:1045-1050. © 2005 American Cancer Society.*

KEYWORDS: cervical carcinoma, low-grade abnormality, screening, cohort study, epidemiology.



High-grade cytology 20,000 women per year
 Low-grade cytology 100,000 women per year

Currently prevent 1200 cancers per year

Still 400 invasive squamous cancers per year in women aged 20-69 yrs, almost all of whom lack a regular screening history

High-grade cytology 20,000 women per year
 Low-grade cytology 100,000 women per year

- Most of the **benefit** comes from treating women with **high-grade** cytology
- Most of the **harm** comes from investigating and treating women with **low-grade** cytology

Low grade abnormalities are the result of a productive HPV infection

“the common cold of sexual activity”

New knowledge

- HPV infection: median clearance time 8 to 14 mths
- Most low-grade lesions regress quite quickly
 - Mean time **10.5 months**
 - **78% regression** at 12 months (95% CI 70-85%)
- Progression from low-grade to high-grade lesion is infrequent and slow
 - Mean time **86.4 months**
 - **3.6% progression** at 12 months (95% CI 0.1-7.1%)

Schlecht JNCI 2003;1336-1343

New knowledge (cont'd)

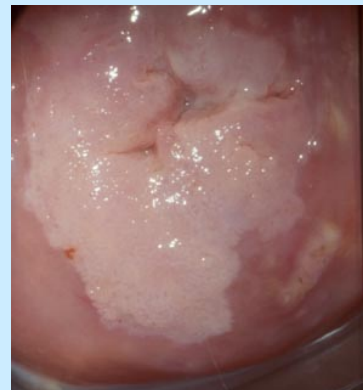- Invasion usually occurs after years of persistence and expansion of CIN 3
- Typically a large amount of CIN 3 present if a woman has microinvasive cancer
- When cytology is reported as low-grade and biopsy shows CIN 3, the amount of CIN 3 is usually very, very small

Cytology	Histology	Mean size of CIN 3 lesion
CIN 1	CIN 3	0.6 mm
CIN 2	CIN 3	5.3 mm
CIN 3	CIN 3	9.5 mm
-	Microcarcinoma & CIN 3	63.5 mm


Tidbury et al 1992

CIN3

Usually high grade Pap smear



Occult high grade with a low grade Pap



**Small lesion:
80% = CIN2**

VCCR 2002

Occult high-grade intraepithelial lesions
(ie cytology low-grade, biopsy high-grade)

- Most of the high-grade lesions (80%+) are CIN 2
- Very unlikely to progress to cancer in 12 months
- 12 months delay in diagnosis will have no effect on cancer incidence in Australia (counterbalanced by earlier colposcopy for women with possible low-grade cytology)

Any extra cancers?

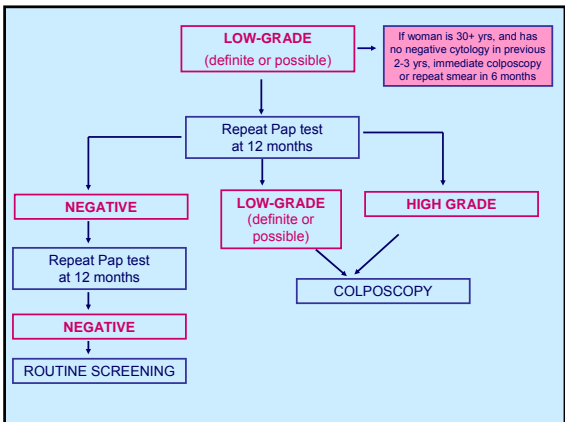
Guidelines Review Group Executive	Oct 2004	Model estimated no extra cancers
Workshop of five independent epidemiologists	Nov 2004	Agreed most likely a neutral effect; any extra cancers would be microinvasive and curable
Independent ANU review	May 2005	Best estimate of 50 fewer cancers (range -9 to -69)

Country	Screening Interval	Cytology	Recommended Management
Finland	5	Pap 1 & 2	Not referred for further exam ⁿ unless repeat cytology or other results are suggestive of cancer
Australia	2	Low-grade	Repeat cytology in 12 months
Canada	3	ASCUS & LSIL	Repeat cytology in 6 months
NZ	3	ASCUS & LSIL	Repeat cytology in 6 months
Netherlands	5	Pap 2 & 3a1 & 3a2	Repeat cytology in 6 months
France	3	ASC-US LSIL	Repeat cyto <u>or</u> colp <u>or</u> HPV testing Repeat cyto at 4-6/12 <u>or</u> colp
USA	3*	ASC-US LSIL	Repeat cyto <u>or</u> colp <u>or</u> HPV testing Colposcopy
UK	3 & 5	Borderline change Mild dyskaryosis	Colposcopy after 3 tests Ideally colp but repeat cytology acceptable

* over 30 yrs of age and after 3 negative tests

How does the policy in Australia compare with other countries?

- No standard policy for women with minor cytological abnormalities operates around the world – varies in each country.
- Australian women with low-grade cytology will be referred for colposcopy at the same time or earlier than women in other countries due to the short screening interval of 2 years in Australia.



Colposcopically assessed and biopsy proven low-grade lesions

- Do not require treatment
- Rather, repeat Pap smear at 12 and 24 mths
 - If these two Pap smears are negative, return to normal screening
 - If either Pap smear shows low-grade change, repeat annually until at least two negative smears, then return to normal screening
 - If repeat Pap smear shows high-grade change, colposcopy

In summary, the low-grade recommendations

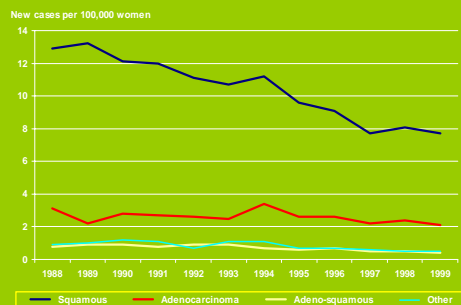
- May result in more colposcopies but fewer treated women
- Colposcopies will be
 - targetted to women who are more likely to have cancer diagnosed in near future (older, under-screened women)
 - focussed on women with persisting abnormal cytology
 - more evenly spread across spectrum of low-grade cytology
- The number of cancers occurring after low-grade cytology will be the same or less

Safety monitoring
of this revised management will occur.

Glandular abnormalities
on Pap smears

- Very rare - about 1 in 1500 women have a Pap smear report of glandular abnormality (cf 75 squamous abns.)
- Important because adenocarcinoma now represents about 20% of all cases of cervical cancer in Australia

Age-standardised incidence rates of cervical cancer by histological type, women aged 20 - 69 years, Australia 1988 - 1999



Terminology for glandular abnormalities on Pap smears

- Atypical cells of undetermined significance (endocervical or glandular)
- Possible high-grade glandular lesions
- Endocervical adenocarcinoma in situ
- Adenocarcinoma

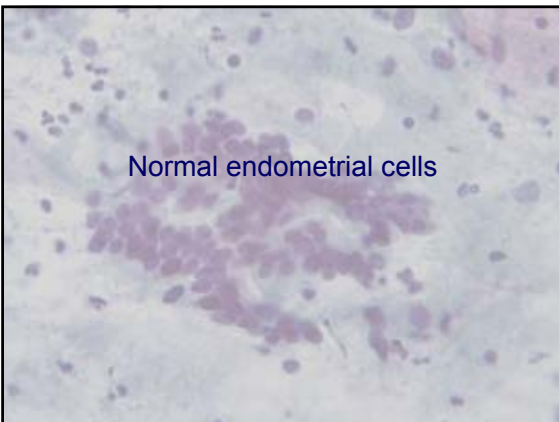
Degree of abnormality on Pap smear	Management	
Atypical cells	Colposcopy	
Possible high-grade	Colposcopy	If TZ is abnormal or not seen, cone biopsy. If colposcopy is normal, cone biopsy or repeat Pap smear and colposcopy at 3/12.
AIS	Colposcopy	Cone biopsy
Adenocarcinoma	Colposcopy	Target (or cone) biopsy

Colposcopy for glandular abnormalities should be performed by a gynaecologist with expertise in suspected malignancies or by a gynaecological oncologist.

Rationale for glandular changes

- Low-grade glandular abnormalities do not exist (acute HPV infection doesn't affect glandular cells)
- Neither cytology nor colposcopy are anatomically well-suited to detecting glandular disease
- Rate of cancer diagnosis within 2 yrs of a glandular abnormality on cytology suggests more intensive investigation is appropriate

Normal endometrial cells



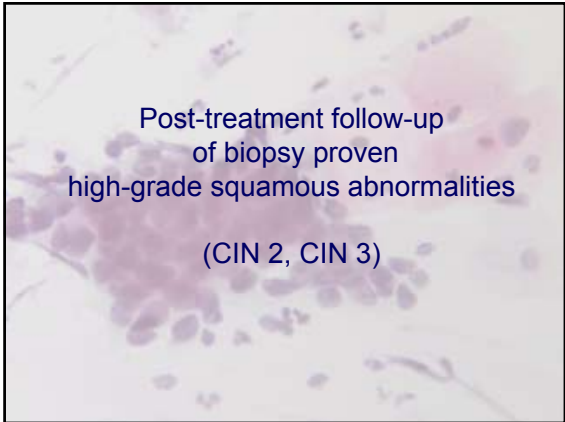
Normal endometrial cells in the Pap smears of asymptomatic postmenopausal women should **not be reported**.

(Symptomatic postmenopausal women require investigation, irrespective of their Pap smear status).

Rationale for not reporting normal endometrial cells

- Very low frequency of having endometrial carcinoma if endometrial cells are normal

Post-treatment follow-up
of biopsy proven
high-grade squamous abnormalities
(CIN 2, CIN 3)



Time since treatment	Pap smear	Colposcopy	HPV typing
4-6 mths	✓	✓	
12 mths	✓		✓
24 mths	✓		✓

- HPV typing is being added to the MBS for this clinical use only ('test of cure')

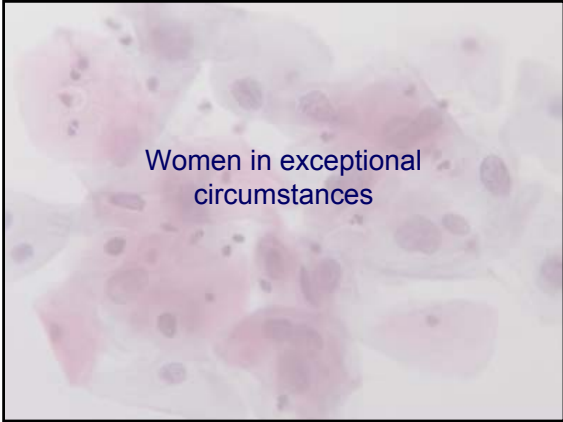Time since treatment	Pap smear	Colposcopy	HPV typing
4-6 mths	✓	✓	
12 mths	Negative		Negative
24 mths	Negative		Negative

- Return to 2 year screening interval when Pap smear and HPV typing are negative on two consecutive occasions

Rationale for post-treatment changes

- Cervical cancer develops in the presence of **persistent** HPV infection
- A negative HPV test very accurately predicts the absence of HPV
- Allows large number of low-risk women (n ≈ 250,000) with treated abnormalities to return to the usual screening interval

Safety monitoring
of this revised management will occur.



The guidelines acknowledge that a different management course may be adopted in exceptional circumstances

- The unduly anxious woman
- The woman who makes a specific request for specialist reassurance
- The geographically isolated woman

a simplified approach to referral

- Squamous abnormality
 - Possible low-grade
 - Low-grade
 } Repeat Pap at 12 months
- Possible high-grade
- High grade
- Glandular abnormality
 - Atypical cells
 - Possible high-grade
 - High grade
 } Colposcopy

National Cervical Screening Program

- **There are no guidelines at present !**
- **New guidelines**
 - are evidence based
 - are needed by practitioners caring for women
 - are needed by women who need information
 - will reduce unnecessary intervention/treatment
 - provide basis for implementation of new terminology
 - endorsed by NHMRC 9th June 2005
 - implementation on 3rd July 2006

New guidelines are now available on line

www.nhmrc.gov.au/publications/synopses/wh39syn.htm